

## COMPARISON OF EFFICACY BETWEEN 0.25% BUPIVACAINE AND 0.25% ROPIVACAINE IN ULTRASOUND GUIDED QUADRATUS LUMBORUM BLOCK FOR POST OPERATIVE ANALGESIA IN PATIENTS UNDERGOING TOTAL ABDOMINAL HYSTERECTOMY

S. Ramadevi<sup>1</sup>, G. Karthikeyan<sup>2</sup>, R. Vijayendran<sup>2</sup>

<sup>1</sup>Associate Professor, Department of Anaesthesiology, Arignar Anna Cancer Hospital, Kanchipuram, Tamil Nadu, India

<sup>2</sup>Senior Assistant Professor, Department of Anaesthesiology, Govt Chengalpattu Medical College, Chengalpattu, Tamil Nadu, India

Received : 07/10/2023  
Received in revised form : 06/12/2023  
Accepted : 22/12/2023

**Keywords:**  
Bupivacaine, Ropivacaine, Quadratus Lumborum Block.

Corresponding Author:  
**Dr. R. Vijayendran,**  
Email: doc1vijay@gmail.com

DOI: 10.47009/jamp.2023.5.6.315

Source of Support: Nil,  
Conflict of Interest: None declared

*Int J Acad Med Pharm*  
2023; 5 (6); 1533-1537



### Abstract

**Background:** Multimodal pain management is always needed to control moderate to severe pain after total abdominal hysterectomy (4). Opioid, which is the analgesic of choice has many adverse effects such as sedation, nausea, and vomiting. Hence, different modalities are needed to control pain. Blanco was the first to describe the Quadratus lumborum block. Somatic pain caused by upper and lower abdominal surgery are controlled by Quadratus Lumborum block. This block uses a fascial layer path for the spread of local anaesthetic into the posterior abdominal wall and paravertebral space. Ropivacaine has a potentially improved safety profile when compared to Bupivacaine. It is less lipophilic than Bupivacaine, is less likely to penetrate large myelinated motor fibers resulting in a relatively reduced motor blockade. The aim of this study is to compare the drug safety and efficacy of Bupivacaine 0.25% and Ropivacaine 0.25% for ultrasound guided Quadratus lumborum block in patients undergoing total abdominal hysterectomy under general anesthesia for postoperative analgesia. Study design is Prospective, randomized, interventional study. **Materials and Methods:** Patients within inclusion criteria selected and counseled. After getting consent, patients who were willing to be included in the study were enrolled and analyzed. For both groups A and B, general anesthesia was given. After the surgical procedure got over, before extubating the patient, for postop analgesia, Quadratus Lumborum block given with either 0.25% Ropivacaine (Group A) or 0.25% Bupivacaine (Group B). **Result:** No difference in onset and duration seen in Group A and Group B when used in equal concentration and provided similar efficacy of Block. **Conclusion:** The Quadratus Lumborum block is an effective analgesic tool for abdominal surgery. This study concludes that there is no difference in onset and duration in 0.25% Bupivacaine and 0.25% Ropivacaine when used in equal concentration and provided similar efficacy when used in Quadratus Lumborum block for providing post operative analgesia after total abdominal hysterectomy surgery. Ropivacaine has potentially improved safety profile compared with Bupivacaine.

## INTRODUCTION

Multimodal pain management is always needed to control moderate to severe pain after total abdominal hysterectomy.<sup>[1-4]</sup> Opioid, which is the analgesic of choice has many adverse effects such as sedation, nausea, and vomiting. Hence, different modalities are needed to control pain. The sensory nerves of the anterolateral abdominal wall, T6-L1, that travel to innervate the abdomen are blocked in TAP block. But

the block is shorter duration and less effective. So an alternative approach of Quadratus Lumborum block was performed. Blanco was the first to describe the Quadratus lumborum block.

This block uses a fascial layer path for the spread of local anaesthetic into the posterior abdominal wall and paravertebral space.

This block is classified anatomically into 3 groups – Lateral QLB, Posterior QLB, Anterior QLB.

Lateral Quadratus Lumborum Block (QLB)

This is done using in plane approach, when the needle is inserted anterior to ultrasound probe, in anteroposterior direction. The anaesthetic gets lodged in the quadratus lumborum lateral border, as it pierced the aponeurosis of transverse abdominis.<sup>[5-10]</sup>

**Posterior Quadratus Lumborum Block (QLB):** This is done in in-plane approach, in needle direction as anteroposterior or posteroanterior. Contradictory to the above, the anaesthetic gets lodged in the quadratus lumborum muscle posterior aspect.

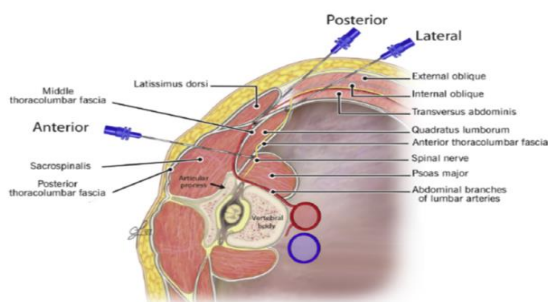
**Anterior Quadratus Lumborum Block (QLB),<sup>[9]</sup>** This is done in in-plane approach, in needle direction as posteroanterior trajectory. Needle direction can be antero posterior also. Contradictory to the above, the anaesthetic gets lodged in the quadratus lumborum muscle posterior aspect.

These above-described methods may differ in needle trajectory that is anterior-to-posterior, caudal-to-cranial, posterior-to-anterior. but the plane of injection is same in all the methods.

Mechanism of action varies with different forms of injection. In the anterior Quadratus lumborum block, anaesthetic may spread to lumbar roots and thoracic paravertebral space. Posterior block spread to thoracolumbar fascia inter transverse area. Lateral block spread via transverse abdominis muscle.<sup>[9-16]</sup>

### Complications

1. Complications related to local anaesthetics: Motor block extension, lower limb weakness.<sup>[17]</sup>
2. Visceral injury due to puncture by the needle
3. Secondary infection in skin
4. Need for further mode of anesthesia if the block fails.
5. Systemic toxicity by the anaesthetic agent
6. Femoral nerve palsy (a rare complication)
7. Complication due to haemorrhagic diathesis.



## MATERIALS AND METHODS

After getting institutional ethical committee approval the study was conducted. Written informed consent was obtained from all subjects. This is a prospective randomized interventional study. Sixty adult female patients of ASA class I and II scheduled for TAH were randomized into two equal groups 30 each. (group A and group B). Randomisation performed by closed envelope technique. Both the groups received general anaesthesia plus quadratus lumborum block, group A with 0.25% Bupivacaine and group B with 0.25% Ropivacaine.

### Inclusion Criteria

- Females giving informed consent.
- Age group 40-65 years
- The American Society of Anesthesiologists Class I & II
- Patients undergoing Elective Total abdominal Hysterectomy

### Exclusion Criteria

- Patients who are not giving consent.
- Patients on cardiac disorders
- Patients with psychiatric disorders
- Patients with renal /hepatic / CNS disease
- The American Society of Anesthesiologists class III & IV
- Patients who have Clotting abnormalities,
- Local infections
- History of allergy to the study medications.

**Anesthesia and surgery procedure:** For both groups, general anesthesia was given by premedicating the patient with IV injection of Fentanyl citrate (1 µg/kg) and induction with Thiopentone sodium (5mg/kg) and then Atracurium besylate (0.5 mg/kg) were injected for endotracheal intubation. Anesthesia was continued with incremental dose of Atracurium besylate (0.1mg/kg) given every 30 min or when needed.

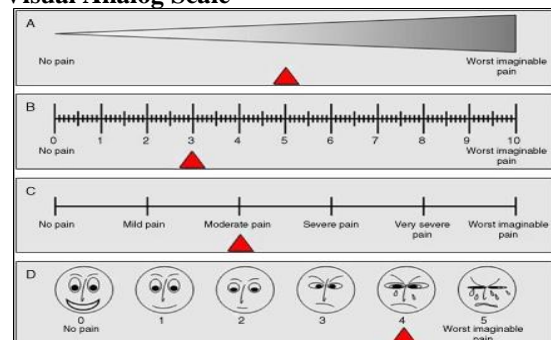
After the surgical procedure got over, before extubating the patient for postop analgesia, under complete aseptic precautions, using ultrasound machine (DS 30) with low frequency(2-5MHz) curvi-linear probe covered with sterile sheath and 100 mm needle, Quadratus Lumborum block given with either 0.25% Bupivacaine or 0.25% Ropivacaine. Patient was monitored for HR, SPO2, SBP, DBP throughout the procedure from preop, intraop and postop period for 24 hours. Each values noted and tabulated. Reading noted at the interval of immediate postop, 3 hrs, 6 hrs, 12hrs and 24 hrs post operative period. In case of inadequate block or block failure rescue analgesia given with tramadol or paracetamol after assessing the pain with visual analogue scale.

### Assessment Criteria

Check for sensation of cold at T6-L1 dermatomes ipsilaterally and compare it with contralateral side.

Successful blockade	Grade 1	Inability to perceive cold sensation at L1 dermatome.
Failed blockade	Grade 0	Patient is able to perceive sensation of cold at L1 dermatomal distribution

### Visual Analog Scale



## Postoperative Analgesic Requirement

Postoperative Tramadol Requirement for first 24 hours	
None	
1-2 doses	
>2 doses	

**Primary outcome:** Duration of postop analgesia

**Secondary outcome:** Number of Doses of rescue analgesia needed postoperatively (Tramadol/paracetamol)

Postoperative Visual analogue Scale score (0 -10)

Time of first rescue analgesia

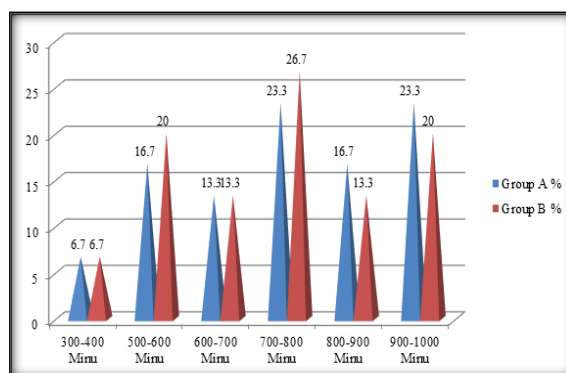
**Observation and Results:** The results from two groups were arranged and evaluated in Master chart.

**Statistical analysis:** The study subjects were described in terms of averages regarding continuous variables and percentages in respect of discrete variables. The continuous variables were compared between the two groups by student independent “t” test. The continuous variables within the group were compared by student paired “t” test. The categorical variables were compared between the two groups by an appropriate non parametric test namely  $\chi^2$  (Chi-square) test. The above statistical procedures were under taken with the help of the statistical package namely IBM SPSS Statistics-20. The P-values less than or equal to 0.05 ( $P \leq 0.05$ ) were considered as statistically significant.

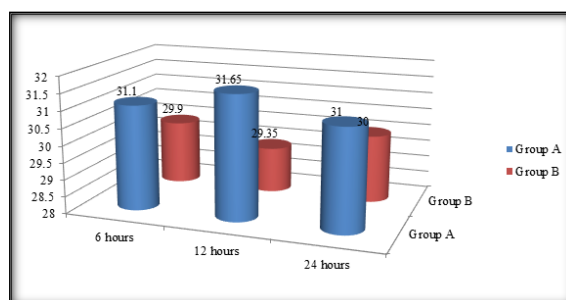
## RESULTS

The table compares the analgesia duration between the groups A&B. The mean duration of group A was  $730.7 \pm 171.0$  minutes. The mean duration of group B was  $716.3 \pm 162.6$  minutes. The difference between the two groups was not statistically significant ( $P > 0.05$ ). [Table 1]

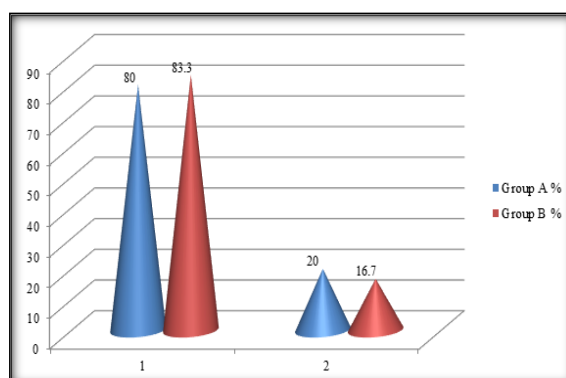
The above [Table 2] compares the pain level between the two groups at 3, 6, 12, and 24 hours. The results revealed that there was no statistically significant pain level between the two groups at 3 hours, 6 hours, 12 hours and 24 hours ( $P > 0.05$ ).



**Figure 1: Comparison of analgesia duration between the two groups A&B:**



**Figure 2: Comparison of VAS of both groups at 6, 12 and 24 hours.**



**Figure 3: Comparison of requirement of OPIOID within 24 hours**

**Table 1: Comparison of analgesia duration between the two groups**

Analgesia duration (minutes)	Group A		Group B	
	Frequency	%	Frequency	%
300-400	2	6.7	2	6.7
500-600	5	16.7	6	20.0
600-700	4	13.3	4	13.3
700-800	7	23.3	8	26.7
800-900	5	16.7	4	13.3
900-1000	7	23.3	6	20.0
Total	30	100.0	30	100.0
Mean± SD	730.7± 171.0		716.3±162.6	
Significance	“t”=0.333, df=58, P=0.740			

**Table 2: Comparison of VAS between groups A&B at 3 hours, 6 hours, 12 hours and 24 hours**

Time	Mean rank of group A	Mean rank of group B	Mann-Whitney -U	“Z”	Sig
3 hours	0	0	0	0	0
6 hours	31.10	29.90	432.0	0.293	P=0.770
12 hours	31.65	29.35	415.0	0.581	P=0.561
24 hours	31.00	30.00	418.0	0.498	P=0.618

**Table 3: Comparison of requirement of OPIOID within 24 hours**

OPIOID	Group -A		Group-B	
	Frequency	%	Frequency	%
1	24	80.0	25	83.3
2	6	20.0	5	16.7
Total	30	100.0	30	100.0
Mean ±SD	1.2±0.4		1.1±0.3	
Significance	“t”=0.328, df=58, P=0.744			

The requirement of OPIOID within 24 hours compared between the two groups. The mean of group A was 1.2±0.4. The mean of group B was 1.1±0.3. The difference between the two groups was not statistically significant (P>0.05).

## DISCUSSION

In this study, comparison of drug safety and efficacy by ultrasound guided Quadratus Lumborum block done with 0.25% Bupivacaine vs 0.25% ropivacaine for postop analgesia in 60 patients undergoing total abdominal hysterectomy under general analgesia who were randomized into two equal groups. Age group was statistically not significant in both groups. The duration of analgesia was similar in group A 730.7± 171.0 minutes and group B was 716.3±162.6 minutes. The requirement of opioid within 24 hours compared to be similar in both group A 1.2±0.4 and group B 1.1±0.3. There were no complications encountered during the study. Also the postoperative VAS scores at 3 to 24 hours shows p> 0.05. Murouchi et al. measured the local anesthetic concentration after the intramuscular Quadratus Lumborum Block . A total of 150mg of Ropivacaine (0.375%, 20mL per side) was administered bilaterally. After administration, arterial Ropivacaine levels were measured using high-performance liquid chromatography with carbamazepine.<sup>[18-20]</sup>

The Ropivacaine concentration was less than 2.2 µg/mL, which represented the arterial and venous threshold values of systemic toxicity. Therefore, the injection of the Quadratus Lumborum block with 150mg of Ropivacaine may be safe. However, immediate transfer to the ward after Quadratus Lumborum block should be avoided, because the Ropivacaine peak was observed around 30 to 60 minutes after the Quadratus Lumborum block.<sup>[21,22]</sup>

BLANCO et al 2015 performed a study on ultrasound guided QuadratusLumborum in caesarian patients for post operative analgesia and concluded that post operative requirements of morphine using visual analog score.<sup>[23,24]</sup>

L. Carline, and L. Colvin et al in his cadaveric study compared spread of dye and nerve involvement with Quadratus lumborum blocks intermuscular, lateral, posterior needle trajectory. The Quadratus lumborum block is very helpful for post operative analgesia in lower abdominal surgeries. Anterior approach is very much effective in lower limb surgeries.<sup>[25]</sup>

There were no studies reporting complications after the QL block. Compared with the TAP block, some Quadratus Lumborum blocks are deep nerve blocks.

Therefore, we must watch sites for infection, blood hematoma, and organ injuries.<sup>[26]</sup>

Absence of control group and extent of anaesthetic in dermatomal plane are the limitations of the study. Quadratus Lumborum block gives sufficient duration of post operative analgesia, reduction of visual analog scores.

Further studies are needed for study on the mechanism and extent of anaesthesia in dermatomal level in Quadratus lumborum block.

## CONCLUSION

The Quadratus Lumborum block is an effective analgesic tool for abdominal surgery. This study concludes that there is no difference in onset and duration in 0.25% Bupivacaine and 0.25% Ropivacaine when used in equal concentration and provided similar efficacy when used in Quadratus Lumborum block for providing post operative analgesia after total abdominal hysterectomy surgery. Ropivacaine has potentially improved safety profile compared with Bupivacaine.

## REFERENCES

1. A. Chakraborty, J. Goswami, and V. Patro, et al “Ultrasound-guided continuous Quadratuslumborum block for postoperative analgesia in a pediatric patient,” A & A Case Reports, vol. 4, no. 3, pp. 34–36, 2015.
2. Adhikary SD, El-Boghdadly K, Nasralah Z, Sarwani N, Nixon AM, Chin KJ:A radiologic and anatomic assessment of injectate spread following transmuscular quadrates lumborum block in cadavers. *Anaesthesia* 2017; 72:73–9
3. Benetazzo L, Bizzego A, De Caro R, Frigo G, Guidolin D, Stecco C: 3D reconstruction of the crural and thoracolumbar fasciae. *Surg Radiol Anat* 2011; 33:855–62
4. Blanco R, Ansari T, Riad W, Shetty N: Quadratus lumborum block versus transversus abdominis plane block for postoperative pain after cesarean delivery: a randomized controlled trial. *Reg Anesth Pain Med* 2016; 41:757–62
5. Børglum J, Gögenür I, Bendtsen TF: Abdominal wall blocks in adults. *Curr Opin Anaesthesiol* 2016; 29:638–43
6. *Clinical anaesthesiology –Morgan and Mikhail's 5th Edition*
7. Cousins & briden baugh s neural blockade in clinical anesthesia and pain medicine20.
8. Dam M, Hansen CK, Børglum J, Chan V, Bendtsen TF: A transverse oblique approach to the transmuscular Quadratuslumborum block. *Anaesthesia* 2016; 71:603–
9. Dam M, Moriggl B, Hansen CK, Hoermann R, Bendtsen TF, Børglum J: The pathway of injectate spread with the transmuscular Quadratuslumborum block: A cadaver study. *Anesth Analg* 2017; 125:303–12
10. *dorsch & dorsch fifth edition*
11. Elsharkawy H, El-Boghdadly K, Kolli S, Esa WAS, degrande S, Soliman LM, Drake RL: Injectate spread following anterior sub-costal and posterior approaches to the Quadratuslumborum block: A comparative cadaveric study. *Eur J Anaesthesiol* 2017; 34:587–95

12. Elsharkawy H. Ultrasound-guided Quadratuslumborum block: How do I do it? ASRA News 2015;15:34-40.
13. Gray's anatomy.the anatomical basis of clinical practice ,fourty first edition,Susan standingr.
14. Harrold Ellis, Ellis Anatomy 11th Edition
15. miller 9 th edition
16. Ng A, Swami A, Smith G, Davidson AC, Emembolu J et al The analgesic effects of intraperitoneal and incisional Bupivacaine with epinephrine after total abdominal hysterectomy. *Anesth Analg* 2002;95:158-62.
17. Oksüz G, Bilal B, Gürkan Y, Urfalioğlu A, Arslan M, Gişi G, Öksüz H: Quadratuslumborum block versus transversus abdominis plane block in children undergoing low abdominal surgery: A randomized controlledtrial. *Reg Anesth Pain Med* 2017; 42:674–9
18. R. Blanco et al “TAP block under ultrasound guidance: the description of a ‘non pops technique’,” *Regional Anesthesia and Pain Medicine*, vol. 32, supplement 1, p. 130, 2007.
19. R. Blanco, T. Ansari, and G. Girgis, et al “Quadratuslumborum block for postoperative pain after caesarean section: a randomized controlled trial,” *European Journal of Anaesthesiology*, vol. 32, no. 11, pp. 812–818, 2015.
20. Sauter AR, Ullensvang K, Niemi G, Lorentzen HT, Bendtsen TF, Børglum J, Pripp AH, Romundstad L: The shamrock lumbar plexus block: A dose-finding study. *Eur J Anaesthesiol* 2015; 32:764–70
21. Stoelting's physiology and pharmacology-5th edition
22. Tulgar S et al Combination of lumbar erector spinae plane block and transmuscular quadratus lumborum block for surgical anaesthesia in hemiarthroplasty for femoral neck fracture. *Indian J Anaesth* 2018;62:802
23. Ueshima H, Hiroshi O: Incidence of lower-extremity muscle weakness after Quadratuslumborum block. *J Clin Anesth* 2018; 44:10
24. V. R. Kadam, et al “Ultrasound-guided Quadratuslumborum block as a postoperative analgesic technique for laparotomy,” *Journal of Anaesthesiology Clinical Pharmacology*, vol. 29, no. 4, pp. 550–552, 2013.
25. Willard FH, Vleeming A, Schuenke MD, Danneels L, Schleich R: et al The thoracolumbar fascia: Anatomy, function and clinical considerations. *J Anat* 2012; 221:507–36
26. Børglum J, Gögenür I, Bendtsen TF: Abdominal wall blocks in adults. *Curr Opin Anaesthesiol* 2016;29:638–43